

Rapunzel Syndrome Presenting as Gastric Perforation: A Case Report

Dr. Thimmaraj Nayaka N S¹, Dr. Mitesh Bedi², Dr. Amol Dhopte³, Dr. Bhupesh Patel⁴, , Dr. Sumita A Jain⁵

¹(Department Of General Surgery, SMS Medical College, Jaipur, India)

²(Department Of General Surgery, SMS Medical College, Jaipur, India)

³(Department Of General Surgery, SMS Medical College, Jaipur, India)

⁴(Department Of General Surgery, SMS Medical College, Jaipur, India)

⁵(Department Of General Surgery, SMS Medical College, Jaipur, India)

Abstract: Rapunzel Syndrome is a rare presentation of trichobezoar in which the tail of the gastric trichobezoar extends up to the intestine. Most cases are seen in young or teenage females, and with a psychiatric disorder. Patients usually present with some complication like obstruction, intususception, delayed gastric emptying, or rarely perforation. Ultrasound, CT, MRI, Barium studies or Endoscopy may aid in diagnosis. We present a case of Rapunzel syndrome presenting as gastric perforation in an adult female, which is exceptional and with very few cases reported in literature.

Keywords: Rapunzel Syndrome, Gastric Perforation, Trichobezoar, Bezoar

I. Introduction

Bezoars are collections of indigestible organic or inorganic foreign material in the gastrointestinal tract, and are classified based on their composition as trichobezoars (hair), phytobezoars (vegetable or fruit fibre), lacto bezoars (milk curd), or any indigestible material. An unusual and rare form of trichobezoar extending from the stomach to the small intestine or beyond has been described as Rapunzel syndrome. First described in 1968 by Vaughan et al [1]; till date only 24 more cases have been reported in the literature [2]. Here we report a rare case of Rapunzel Syndrome presenting as gastric perforation.

II. Case Report

A 20 year old female presented with sudden onset, severe abdominal pain, initially in the epigastric region but later diffuse in distribution, along with obstipation and frequent vomiting for 2 days. There was no history of any drug intake or fever prior to the present episode of pain.

On examination patient was dehydrated and febrile with tachycardia and hypotension. The abdomen was distended, bowel sounds were absent and liver dullness was obliterated. The erect abdominal X-ray showed free air under diaphragm. Rest of the systemic examination was insignificant. With the diagnosis of perforation peritonitis, the patient was taken for emergency laparotomy after adequate resuscitation.

An exploratory laparotomy through midline incision was performed. After draining of the contaminated fluid, which was about 200 ml. abdomen was explored systematically; stomach was hard on palpation, giving an impression of a malignancy. A small perforation of size ~0.5*0.5 cm was present in antrum with few tufts of hair jutting from it. A gastrotomy with longitudinal incision in the anterior wall was performed and a ball of hair, which had assumed the shape of stomach, along with a long tail extending up to jejunum, was removed and anterior gastrotomy closed.

The post operative period was uneventful, and the patient was started on oral diet by the 5th day. Patient was discharged on day 7th and advised psychiatric follow-up.

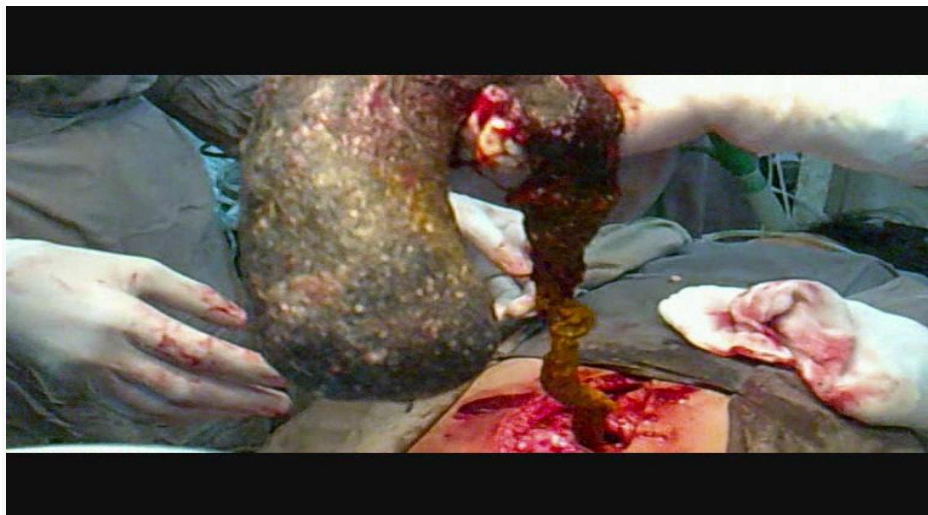


Figure 1. Intra-operative appearance of bezoar during laparotomy

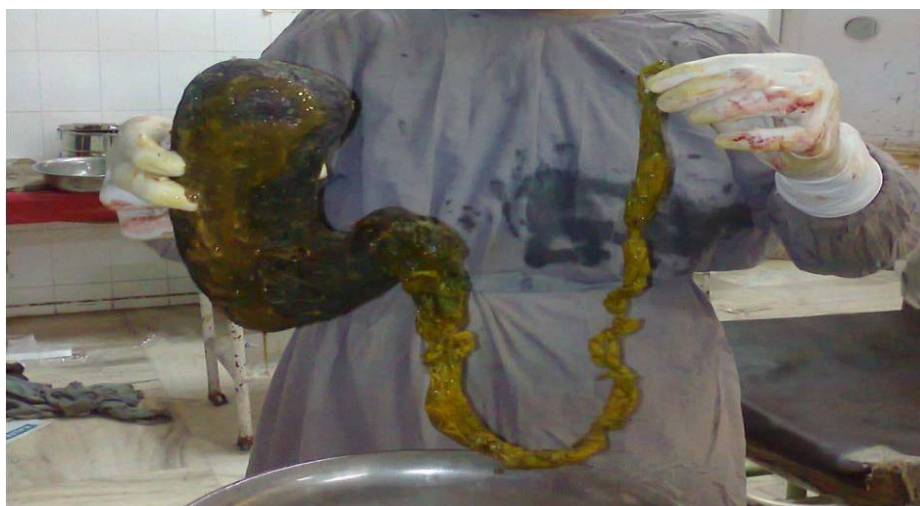

Figure 2: The Trichobezoar alongwith its tail

III. Discussion

Trichobezoars are collections of hair which accumulate and remain within the gastrointestinal tract for extended periods. These occur almost exclusively in females with a history of trichotillomania, trichophagia or gastric dysmotility. A rare presentation includes extension of hair from the stomach throughout the small bowel or even upto large bowel, a phenomenon known as Rapunzel syndrome.

Diagnosis of the condition is difficult and is mostly observed intra-operatively or on endoscopy [4]. Imaging modalities , such as Ultrasound which shows an acoustic shadow of the solid mass surrounded by an echogenic arc of air ,CT which shows a free floating filling defect within the stomach or intestine , MRI or barium study may also aid in the diagnosis of the condition ,but endoscopy has the advantage of a therapeutic option as well [3,4].

Treatment involves removal of the offending accumulated concretions, and is based on the size and composition of the bezoar.Observation, chemical dissolution, fragmentation or endoscopic retrieval are the treatment options in small size trichobezoars[4,5]. As gastric trichobezoars are generally more difficult to remove endoscopically, most of the reported cases required surgery with both conventional laparotomy as well as laparoscopic approaches being mentioned in the literature [7].The first successful laparoscopic removal of a gastric bezoar was reported in 1998 by Nirasawa et al [6], with few reports of successful laparoscopic removal published thereafter [7]. Laparoscopic removal, though superior to open laparotomy, warrants careful patient selection and patients who are unstable or critically ill may not be appropriate candidates for laparoscopic intervention. In Rapunzel syndrome, though, conventional laparotomy is still the only valid option as the long jejunal tail requires careful manipulation and carries risk of spillage in laparoscopic procedure [7]. Psychiatric consultation forms an essential part of the management [8].

REFERENCES

- [1]. Vaughan ED Jr, Sawyers JL, Scott HW Jr. The Rapunzel Syndrome. An Unusual Complication Of Intestinal Bezoar. *Surgery* 1968; 63:339-43.
- [2]. Naik S, Gupta V, Naik S, Rangole A, Chaudhary AK, Jain P, Sharma AK. Rapunzel Syndrome Reviewed and Redefined. *Dig Surg* 2007; 24: 157-161
- [3]. Ripollés T, García-Aguayo J, Martínez MJ, Gil P. Gastrointestinal Bezoars: Sonographic And CT characteristics. *AJR Am J Roentgenol* 2001; 177:65-9.
- [5]. De Backer A, Van Nooten V, Vandenplas Y. Huge Gastric Trichobezoar In a 10-year-old girl: Case Report With Emphasis On Endoscopy In Diagnosis And Therapy. *J Pediatr Gastroenterol Nutr* 1999; 28:513-5.
- [6]. Tiwary S K, Kumar S, Khanna R, Khanna A K. Recurrent Rapunzel Syndrome. *Singapore Med J* 2011; 52(6): e128-e130.
- [7]. Nirasawa Y, Mori T, Ito Y, Tanaka H, Nobuo S, Atomi Y. Laparoscopic Removal Of A Large Gastric Trichobezoar. *J Pediatr Surg*. 1998;33(4):663– 635
- [8]. Management Of Trichobezoar: Case Report And Literature Review. Gorter RR, Kneepkens CM, Mattens EC, Aronson DC, Heij HA. *Pediatr Surg Int*. 2010 May; 26(5):457-63.
- [9]. Miltenberger RG, Rapp JT, Long ES. Habit Reversal Treatment Manual for Trichotillomania. In: Woods D, Miltenberger R, eds. *Tic Disorders, Trichotillomania, and Other Repetitive Behavior Disorders: Behavioral Approaches to Analysis and Treatment*. Boston: Kluwer Academic, 2001: 170-95.